

# Thyroid Imaging Reporting and Data System for US Features of Nodules: A Step in Establishing Better Stratification of Cancer Risk<sup>1</sup>

Jin Young Kwak, MD  
Kyung Hwa Han, MS  
Jung Hyun Yoon, MD  
Hee Jung Moon, MD  
Eun Ju Son, MD  
So Hee Park, MD  
Hyun Kyung Jung, MD  
Ji Soo Choi, MD  
Bo Mi Kim, MD  
Eun-Kyung Kim, MD

## Purpose:

To develop a practical thyroid imaging reporting and data system (TIRADS) with which to categorize thyroid nodules and stratify their malignant risk.

## Materials and Methods:

The institutional review board approved this retrospective study, and the requirement to obtain informed consent for the review of images and records was waived. From May to December 2008, ultrasonographically (US)-guided fine-needle aspiration biopsy (FNAB) was performed in 3674 focal thyroid nodules in 3414 consecutive patients. The study included the 1658 thyroid nodules ( $\geq 1$  cm in maximum diameter at US) in 1638 patients (1373 women, 265 men) for which pathologic diagnosis or follow-up findings were available. Univariate and multivariate analyses with generalized estimating equations were performed to investigate the relationship between suspicious US features and thyroid cancer. A score for each significant factor was assigned and multiplied by the  $\beta$  coefficient obtained for each significant factor from multivariate logistic regression analysis. Scores for each significant factor were then added, resulting in an equation that fitted the probability of malignancy in thyroid nodules. The authors evaluated the fitted probability by using a regression equation; the risk of malignancy was determined according to the number of suspicious US features.

## Results:

The following US features showed a significant association with malignancy: solid component, hypoechogenicity, marked hypoechogenicity, microlobulated or irregular margins, microcalcifications, and taller-than-wide shape. As the number of suspicious US features increased, the fitted probability and risk of malignancy also increased. Positive predictive values according to the number of suspicious US features were significantly different ( $P < .001$ ).

## Conclusion:

Risk stratification of thyroid malignancy by using the number of suspicious US features allows for a practical and convenient TIRADS.

© RSNA, 2011

<sup>1</sup>From the Department of Radiology, Research Institute of Radiological Science (J.Y.K., J.H.Y., H.J.M., E.J.S., S.H.P., H.K.J., J.S.C., B.M.K., E.K.K.), and Department of Research Affairs (K.H.H.), Yonsei University College of Medicine, 250 Seongsanno, Seodaemun-gu, Seoul 120-752, Korea. Received January 31, 2011; revision requested March 18; revision received April 18; accepted May 2; final version accepted May 17. Supported by a faculty research grant from Yonsei University College of Medicine for 2010 (6-2010-0151). Address correspondence to E.K.K. (e-mail: [ekkim@yuhs.ac](mailto:ekkim@yuhs.ac)).

The widespread use of ultrasonography (US) has contributed to the increased detection of thyroid nodules. Thyroid US depicts nodules in up to 67% of the population (1). However, less than 10% of these nodules are malignant (2,3). Although many reports have demonstrated malignant US features that necessitate US-guided fine-needle aspiration biopsy (FNAB) (2,4–11), it is still difficult to decide which lesions should undergo FNAB because the same thyroid nodule may be classified in different ways with different guidelines (2,4–8). Therefore, it may be confusing to determine which guideline to use when deciding whether to perform FNAB in a thyroid nodule.

Recently, two reports have suggested a reporting data system for thyroid lesions in stratifying the malignant risk of nodules (12,13). The authors used the categorization system of US features in thyroid nodules and demonstrated the risk of malignancy in each category. These two classification systems are based on the Breast Imaging Reporting and Data System (BI-RADS), which was developed by the American College of Radiology (14). The BI-RADS has been designed to help standardize breast imaging reports, final assessments, and the management of breast lesions, resulting in better communication between clinicians and radiologists (14). The final

assessment categories in the BI-RADS classification range from 1 (negative findings) to 6 (known proved malignancy). Categories 2–5 are distinguished according to the level of suspicion for malignancy (14). Among them, differentiating category 3 from category 4 lesions is crucial because the former usually undergo imaging follow-up and the latter necessitate biopsy confirmation. To enable better communication with the referring physicians and patients, category 4 was further divided into subcategories 4a (low suspicion), 4b (intermediate suspicion), and 4c (moderate suspicion). According to definitions in BI-RADS (14), a lesion assigned to BI-RADS category 3 should have a malignancy risk of less than 2%, a lesion assigned to BI-RADS categories 4a, 4b, and 4c should have a malignancy risk of 2%–10%, 10%–50%, and 50%–95%, respectively, and a lesion assigned to BI-RADS category 5 should have a high probability ( $\geq 95\%$ ) of being cancer.

Although previous investigators have tried to develop a thyroid imaging reporting and data system (TIRADS), both systems were difficult to apply in the clinical field because of their complexity (12,13). The aim of our study was to develop a practical TIRADS with which to categorize thyroid nodules and stratify their malignant risk.

in 3414 consecutive patients. Nodules were included in the study if their maximal diameter at US was at least 1 cm. Of the 3674 nodules, 1972 met the size criteria. Patients were included if they (a) had benign or malignant results at cytologic examination and (b) underwent thyroid surgery after specimens from cytologic examination were classified as suspicious for papillary thyroid carcinoma, indeterminate (eg, follicular or Hürthle cell neoplasm), or inadequate. Among the 1972 nodules examined, 314 were excluded because they were suspicious for papillary thyroid carcinoma ( $n = 8$ ), were indeterminate ( $n = 8$ ), or had inadequate results ( $n = 298$ ) at cytologic examination but did not undergo surgery. This study included 1658 thyroid nodules in 1638 patients (1373 women and 265 men) (Fig 1). Of the 1638 patients, 1233 had one thyroid nodule, 248 had two nodules, 79 had three nodules, and 78 had more than four nodules measuring at least 1 cm in maximum diameter at US. Our study included the 1618 patients who underwent US-guided FNAB of only one nodule and the 20 patients who underwent US-guided FNAB of two thyroid nodules (Table 1). Patients ranged in age from 11 to 81 years (mean, 50.6 years). The mean age of male patients was 52.2 years

### Advances in Knowledge

- The following US features are significantly associated with thyroid cancer: solid component, hypoechoogenicity, marked hypoechoogenicity, microlobulated or irregular margins, microcalcifications, and taller-than-wide shape.
- As the number of suspicious US features increased, the fitted probability and risk of malignancy also increased; values of fitted probabilities and risk of malignancy were, respectively, 0.036–0.127 and 0.033 in patients with one suspicious US feature and 0.887–0.979 and 0.875 in patients with all five suspicious US features.

### Materials and Methods

#### Study Population

The institutional review board approved this retrospective study, and the requirement to obtain informed consent was waived. This study was performed at our institution (a referral center) from May to December 2008. During this period, US-guided FNAB was performed in 3674 focal thyroid nodules

#### Implication for Patient Care

- Risk stratification of thyroid malignancy by using the number of suspicious US features allows for a practical and convenient thyroid imaging reporting and data system.

#### Published online before print

10.1148/radiol.11110206 Content codes: **HN** **US**

**Radiology** 2011; 260:892–899

#### Abbreviations:

BI-RADS = Breast Imaging Reporting and Data System  
FNAB = fine-needle aspiration biopsy  
TIRADS = thyroid imaging reporting and data system

#### Author contributions:

Guarantors of integrity of entire study, J.Y.K., S.H.P., B.M.K., E.K.K.; study concepts/study design or data acquisition or data analysis/interpretation, all authors; manuscript drafting or manuscript revision for important intellectual content, all authors; manuscript final version approval, all authors; literature research, H.K.J., B.M.K.; clinical studies, J.Y.K., H.J.M., S.H.P., H.K.J., B.M.K., E.K.K.; experimental studies, H.K.J., B.M.K.; statistical analysis, K.H.H., H.K.J., B.M.K.; and manuscript editing, J.H.Y., H.J.M., E.J.S., H.K.J., B.M.K., E.K.K.

Potential conflicts of interest are listed at the end of this article.

**Table 1**

**Number of Thyroid Nodules Evaluated in the 1638 Patients**

No. of Nodules Detected at US	No. of Patients Included (n = 1638)	No. of Patients with Only One Nodule Aspirated (n = 1618)	No. of Patients with Two Nodules Aspirated (n = 20)	No. of Included Nodules That Were Aspirated (n = 1658)
1	1233	1233	0	1233
2	248	234	14	262
3	79	75	4	83
≥4	78	76	2	80

**Table 2**

**Histopathologic Findings in the 298 Nodules Treated with Surgery**

Finding	No. of Nodules
<b>Malignant (n = 238)</b>	
Papillary carcinoma	226 (95)
Follicular variant of papillary carcinoma	5 (2.1)
Medullary carcinoma	3 (1.3)
Minimally invasive follicular carcinoma	1 (0.4)
Widely aggressive follicular carcinoma	1 (0.4)
Poorly differentiated carcinoma	1 (0.4)
Anaplastic carcinoma	1 (0.4)
<b>Benign (n = 60)</b>	
Adenomatous hyperplasia	53 (88)
Follicular adenoma	4 (6.7)
Hürthle cell adenoma	2 (3.3)
Hyalinizing trabecular tumor	1 (1.7)

Note.—Numbers in parentheses are percentages.

**Figure 1**

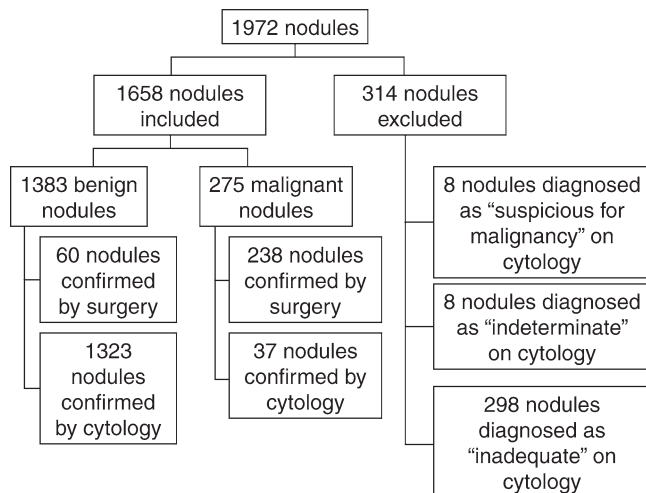


Figure 1: Diagram of the study group.

(range, 14–81 years), and the mean age of female patients was 50.3 years (range, 11–81 years). The mean nodule size (±standard deviation) was 19.9 mm ± 11 (range, 10–80 mm).

**Imaging and Imaging Analyses**

US scans of the thyroid glands and neck areas were obtained by using a 5–12-MHz linear-array transducer (iU22; Philips Medical Systems, Bothell, Wash). Both compound and conventional imaging were performed in all patients. Real-time US was performed by seven radiologists (four radiologists with 5–13 years of experience and three fellows). At US, the thyroid nodules that underwent US-guided FNAB were described according to the internal component, echogenicity, margins, evidence of calcifications, and shape at the time of FNAB (4). The internal component of the nodules was classified as solid or mixed solid and

cystic. Masses with mixed components were evaluated on the basis of the internal solid components. Echogenicity was classified as hyperechogenicity, isoechogenicity, hypoechogenicity, or marked hypoechogenicity. When the echogenicity of the nodule was similar to that of the thyroid parenchyma, it was classified as isoechoic. The nodule was classified with marked hypoechogenicity if the echogenicity was less than that of the surrounding strap muscle. Margins were classified as well circumscribed, microlobulated, or irregular. A microlobulated margin was defined as the presence of many small lobules on the surface of a nodule. Calcifications, when present, were categorized as microcalcifications or macrocalcifications. Microcalcifications were defined as calcifications that were equal to or less than 1 mm in diameter and visualized as tiny punctate hyperechoic foci, either

with or without acoustic shadows. If tiny bright reflectors with a clear-cut comet-tail artifact were present at conventional US, we considered those as colloid (15). Macrocalcifications were defined as hyperechoic foci larger than 1 mm. When a nodule had both types of calcifications (macrocalcifications, including rim calcifications, intermingled with microcalcifications), we regarded it as having microcalcifications. Shape was categorized as taller than wide (greater in its anteroposterior dimension than in its transverse dimension) or wider than tall. In our institution, US findings of microcalcifications, irregular or microlobulated margins, marked hypoechogenicity, and taller-than-wide shape are considered indicative of malignancy. Nodules showing at least one of the suspicious findings were considered suspicious for malignancy.

**US-guided FNAB**

After US evaluation of the thyroid gland, US-guided FNAB was performed by the same radiologists who performed the US evaluation. At our institution, US-guided FNAB is performed in either the thyroid nodule with suspicious US features or the largest thyroid nodule if

Table 3

## Association between Thyroid Malignancy and Various US Features

Parameter	No. of Malignant Nodules ( <i>n</i> = 275)*	No. of Benign Nodules ( <i>n</i> = 1383)*	Univariate Analysis		Multivariate Analysis	
			Odds Ratio <sup>†</sup>	<i>P</i> Value <sup>‡</sup>	Odds Ratio <sup>†</sup>	<i>P</i> Value <sup>§</sup>
<b>Composition</b>						
Solid ( <i>n</i> = 1060)	255 (24.1)	805 (75.9)	9.155 (5.745, 14.587)	...	1.796 (1.063, 3.031)	.029
Mixed ( <i>n</i> = 598)	20 (3.3)	578 (96.7)	1	...	1	...
<b>Echogenicity</b>						
Hyper/isoechoogenicity ( <i>n</i> = 900)	43 (4.8)	857 (95.2)	1	...	1	...
Hypoechoogenicity ( <i>n</i> = 677)	169 (25.0)	508 (75.0)	6.630 (4.635, 9.486)	...	1.955 (1.264, 3.023)	.003
Marked hypoechoogenicity ( <i>n</i> = 81)	63 (77.8)	18 (22.2)	69.756 (37.216, 130.747)	...	3.828 (1.627, 9.010)	.002
<b>Margins</b>						
Well circumscribed ( <i>n</i> = 1330)	68 (5.1)	1262 (94.9)	1	...	1	...
Microlobulated ( <i>n</i> = 221)	115 (52.0)	106 (48.0)	20.135 (14.038, 28.880)	...	4.993 (3.061, 8.146)	<.001
Irregular ( <i>n</i> = 107)	92 (86.0)	15 (14.0)	113.828 (60.771, 213.205)	...	15.364 (7.179, 32.883)	<.001
<b>Calcifications</b>						
Microcalcifications ( <i>n</i> = 162)	111 (68.5)	51 (31.5)	25.871 (17.503, 38.240)	...	5.908 (3.395, 10.283)	<.001
Macrocalcifications ( <i>n</i> = 246)	67 (27.2)	179 (72.8)	4.449 (3.119, 6.346)	...	1.414 (0.890, 2.247)	.142
No calcifications ( <i>n</i> = 1250)	97 (7.8)	1153 (92.2)	1	...	1	...
<b>Shape</b>						
Wider than tall ( <i>n</i> = 1460)	134 (9.2)	1326 (90.8)	1	...	1	...
Taller than wide ( <i>n</i> = 198)	141 (71.2)	57 (28.8)	24.478 (17.152, 34.933)	...	3.662 (2.182, 6.147)	<.001

\* Numbers in parentheses are percentages.

<sup>†</sup> Numbers in parentheses are 95% confidence intervals.

<sup>‡</sup> Determined with the  $\chi^2$  test.

<sup>§</sup> Determined with logistic regression analysis.

no suspicious US features are detected. US-guided FNAB was performed with a 23-gauge needle attached to a 2-mL disposable plastic syringe and aspirator. Each lesion was aspirated at least twice. Materials obtained from aspiration biopsy were expelled onto glass slides and smeared. All smears were placed immediately in 95% alcohol for Papanicolaou staining. The remainder of the aspirated material was rinsed in saline for cell block processing. Cytopathologists were not on site during the biopsy. Additional special staining was performed on a case-by-case basis according to the cytopathologist's needs. One of five cytopathologists specializing in thyroid cytology interpreted the smears obtained with FNAB. During the study period, the cytology reports at our institution were classified as (a) benign, (b) indeterminate, (c) suspicious for papillary thyroid carcinoma, (d) malignant, or (e) inadequate (16). After December 2009, the Bethesda system was used to classify cytologic results in our institution (17). Specimens considered indeterminate at

cytologic examination included follicular or Hürthle cell neoplasms, meaning that the specimen demonstrated a monotonous cellular population and scant colloid but lacked features of papillary carcinoma (18). A specimen was considered suspicious for papillary thyroid carcinoma when it manifested varying cytologic abnormalities associated with papillary carcinoma (eg, nuclear membrane irregularity, nucleolar abnormalities, abnormal nucleus-to-cytoplasm ratios) but did not fulfill the criteria for a diagnosis of papillary carcinoma (19). A specimen was considered inadequate if it showed less than a minimum of six groupings of well-preserved thyroid cells consisting of fewer than 10 cells per group (6).

#### Data and Statistical Analysis

Patients with benign or malignant thyroid nodules were compared according to sex and US features by using a  $\chi^2$  test. An independent two-sample *t* test was used to compare patient age and nodule size at US between benign and malig-

nant nodules. Associations between US features and malignancy were also evaluated by using logistic regression analysis with a generalized estimating equation to consider effects of multiple nodules per individual.

With adjustment for all variables, multivariate logistic regression analysis with generalized estimating equations was performed to determine independent predictors of malignancy from the US characteristics that showed statistical significance. After analysis, we obtained a regression equation for fitting the probability of malignancy in thyroid nodules. Scores for each significant factor were multiplied by the  $\beta$  coefficient obtained for each significant factor from multivariate logistic regression analysis with generalized estimating equations. To evaluate the distribution of fitted probabilities associated with the number of suspicious US features, for all possible combinations of the dichotomous feature variables included in the multivariable model, we estimated the logit (as the intercept plus the sum of



the  $\beta$  values multiplied by the given level of feature variable), which was subsequently used for estimating the fitted probabilities. The Cochran-Armitage trend test was used to evaluate the linear association between the number of suspicious US features in thyroid nodules and the probability of malignancy. Odds ratios with relative 95% confidence intervals were also calculated to determine the relevance of all potential predictors of outcome.

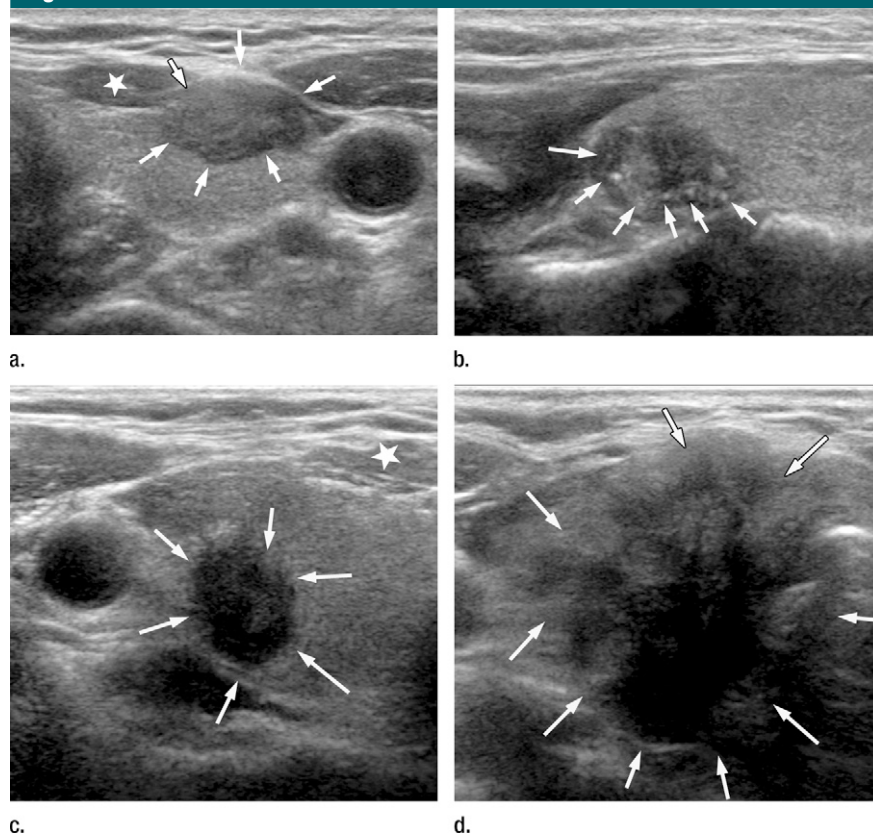
Analysis was performed by using software (SAS, version 9.1.3; SAS Institute, Cary, NC).  $P < .05$  was indicative of a statistically significant difference. All reported  $P$  values are two-sided.

## Results

Of the 1658 nodules, 1383 were benign and 275 were malignant. Sixty benign and 238 malignant nodules were confirmed with surgery, and 1323 benign and 37 malignant nodules were confirmed with cytologic examination (Fig 1). The pathologic diagnoses of the 298 thyroid nodules that had undergone surgery are listed in Table 2. Benign nodules were significantly larger than malignant nodules (mean size,  $20.7 \text{ mm} \pm 11.4$  vs  $15.5 \text{ mm} \pm 7.5$ , respectively;  $P < .001$ ). Patients with benign nodules were older than those with malignant nodules (mean age,  $51.2 \text{ years} \pm 12.3$  vs  $47.5 \text{ years} \pm 13.7$ , respectively;  $P < .001$ ). There was no statistically significant relationship between the risk of malignancy and sex.

At univariate analysis, the following US features showed a significant association with malignancy: solid component, hypoechoogenicity, marked hypoechoogenicity, microlobulated or irregular margins, microcalcifications, and taller-than-wide shape (Table 3, Fig 2). Multivariate analysis showed that the risk of malignancy increased as the number of suspicious US features increased (Table 3, Fig 3). Values of fitted probabilities and risk of malignancy were 0.02–0.028 and 0.017, respectively, in nodules with no suspicious US features, 0.036–0.127 and 0.033 in those with one suspicious US feature, 0.068–0.378 and 0.092 in those with two suspicious

**Figure 2**



**Figure 2:** US scans show features indicative of malignancy, including (a) hypoechoogenicity ( $\star$  = strap muscle, arrows = nodule); (b) microcalcifications (arrows); (c) marked hypoechoogenicity ( $\star$  = strap muscle, arrows = nodule), microlobulated margin, and taller-than-wide shape; and (d) irregular margin (arrows = nodule).

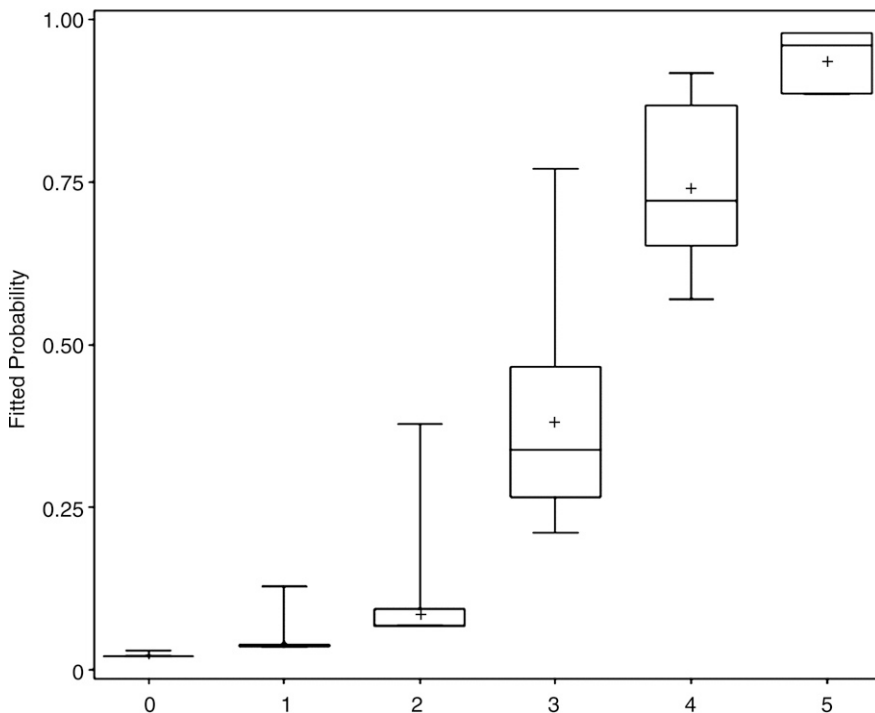
US features, 0.21–0.771 and 0.444 in those with three suspicious US features, 0.57–0.919 and 0.724 in those with four suspicious US features, and 0.887–0.979 and 0.875 in those with all five suspicious US features. Among the suspicious US features, each had a variety of ranges in the fitted probability of malignancy from 0.036 to 0.109 (0.036–0.05 in nodules with solid component alone, 0.039–0.054 in nodules with hypoechoogenicity alone, 0.127 in nodules with microlobulated margins alone, and 0.109 in nodules with microcalcifications alone). The values of fitted probabilities in thyroid nodules with a microlobulated margin and microcalcifications were 0.127 and 0.109, respectively, which were higher than those (0.068–0.093) in nodules with two suspicious US features—solid component and hypoechoogenicity—combined. In

addition, the risk of malignancy according to the number of suspicious US features was significantly different ( $P < .001$ ). According to the results of the Cochran-Armitage trend test, as the number of suspicious US features increased, the probability of malignancy increased ( $P < .001$ ). With these findings, we created TIRADS category 3 (no suspicious US features), 4a (one suspicious US feature), 4b (two suspicious US features), 4c (three or four suspicious US features), and 5 (five suspicious US features) (Table 4) using the risk of malignancy from the BI-RADS categorization.

## Discussion

The improved detection of thyroid nodules with US has resulted in an increase in the number of thyroid FNABs and,

Figure 3



**Figure 3:** Box plot shows fitted probabilities of malignancy calculated with logistic regression by using US features of the 1658 thyroid nodules. Probabilities are shown according to number of suspicious US features (x-axis). The lower and upper ends of vertical lines are minimum and maximum values of the probability of malignancy. The upper edge of the box is the 75th percentile of the data set; lower hinge represents the 25th percentile. The line in the box represents the median, and points indicated by + are means.

thus, an increase in the number of thyroid cancers diagnosed (20,21). Appropriate criteria are necessary to avoid an increase of rather unnecessary benign cytologic results in thyroid nodules. Although many guidelines and studies suggest that suspicious US features should be considered when selecting which thyroid nodules should be biopsied (2,4–11), we still need better guidelines for facilitating US reports in order to communicate with and reduce confusion among physicians and patients—issues that are similar to the ones that brought about the creation of BI-RADS categorizations (12–14,22,23).

The terminology of TIRADS was first used by Horvath et al (13). They described 10 US patterns of thyroid nodules and related the rate of malignancy according to the pattern (13). However, these US patterns were not applicable to all thyroid nodules and this stereotypic US application is difficult for US

performers to use. Therefore, it is not easy to apply this kind of approach to clinical practice. Shortly after the study by Horvath et al, Park et al (12) proposed an equation for predicting the probability of malignancy in thyroid nodules on the basis of 12 US features. Although this approach makes it possible to stratify nodules into categories, it can be difficult to assign every thyroid nodule into the equation proposed in clinical practice. Therefore, we investigated a practical and convenient TIRADS for the management of thyroid nodules.

Our classification system is similar to BI-RADS and was based on both fitted probability and risk of malignancy. Several US features, such as hypoechoogenicity, marked hypoechoogenicity, microlobulated or irregular margins, microcalcifications, and taller-than-wide shape, were regarded as independent US features of malignancy. The US features that were classified as suspicious

in our study are similar to those used by the American Association of Clinical Endocrinologists (24). Frates et al (25) suggested that the presence of coarse or rim calcifications increased the likelihood of cancer almost twofold, with the presence of punctate calcifications increasing the likelihood of cancer almost threefold. Our results suggest that macrocalcifications (without associated microcalcifications) are not a risk factor for malignancy.

We found that as the number of suspicious US features increased, fitted probability and risk of malignancy also increased. This result can support the comments of the American Association of Clinical Endocrinologists in that the coexistence of at least two suspicious US features greatly increases the risk of thyroid cancer (24). In our study, thyroid nodules with no suspicious US features had a 0.02–0.028 fitted probability of malignancy, which may indicate that it is safe to follow up the mass rather than proceed with biopsy. Nodules classified as TIRADS 4 or 5 (at least one suspicious US feature), however, had more than 0.036 fitted probability of malignancy, making them candidates for biopsy just as with the BI-RADS (14).

This new TIRADS can be easily applied in the clinical field because it is not difficult for those who perform US to count the number of suspicious US features. However, there are several limitations to this study. First, we followed up only a subset of our population. Because some of our initial population did not undergo follow-up, selection bias may have existed. Second, the results of this study are from a single institution. However, seven radiologists were involved in performing and interpreting US examinations in our hospital, reflecting the expected variation among readers that inevitably exists in clinical practice (26). More studies in which the TIRADS is prospectively applied at various organizations (as the American College of Radiology did with the BI-RADS) are needed in the future for verification of TIRADS. Third, we regarded stable nodules with benign initial cytologic results as benign and nodules with

**Table 4**

**Comparison of Several Classification Systems**

Study and Parameter	Category				
	1	2	3	4	5
<b>Horvath et al (13)</b>					
Definition	Benign	Benign	Probably benign	4a: undetermined; 4b: suspicious	Consistent with malignancy
Proposed risk of malignancy	0	0	<5	4a: 5–10; 4b: 10–80	>80
Risk of malignancy	0	0	14.1	45	89.6
<b>Park et al (12)</b>					
Definition	Highly suggestive of benignity	Probably benign	Indeterminate	Probably malignant	Highly suggestive of malignancy
Probability*	0–7	8–23	24–50	51–90	91–100
Risk of malignancy	1.8	9.6	31.1	76.8	100
<b>BI-RADS (14)</b>					
Definition	Negative	Benign	Probably benign	4a: low suspicion for malignancy; 4b: intermediate suspicion for malignancy; 4c: moderate concern but not classic for malignancy	Highly suggestive of malignancy
Risk of malignancy	0	0	<2	4a: 2–10; 4b: 10–50; 4c: 50–95	>95
<b>Current study</b>					
Definition	Negative	Benign	Probably benign (no suspicious US features)	4a: low suspicion for malignancy (one suspicious US feature); 4b: intermediate suspicion for malignancy (two suspicious US features); 4c: moderate concern but not classic for malignancy (three or four suspicious US features)	Highly suggestive of malignancy (five suspicious US features)
Fitted probability <sup>†</sup>	0	0	2–2.8	4a: 3.6–12.7; 4b: 6.8–37.8; 4c: 21–91.9	88.7–97.9
Risk of malignancy	0	0	1.7	4a: 3.3; 4b: 9.2; 4c: 44.4–72.4	87.5

\* Data are ranges of the fitted probability of a nodule being malignant based on an equation derived from US features.

<sup>†</sup> The fitted probability for malignancy was calculated as follows:  $\frac{\exp(\text{equation})}{1 + \exp(\text{equation})}$ , where the equation =  $-3.8809 + (0.5852 \times \text{US1}) + (0.6702 \times \text{US2}) + (1.3424 \times \text{US3}) + (1.6081 \times \text{US4}) + (2.7320 \times \text{US5}) + (1.7764 \times \text{US6}) + (0.3466 \times \text{US7}) + (1.2981 \times \text{US8})$ . US1: solid composition = 1, mixed composition = 0; US2: hypoechoogenicity = 1, other echogenicity = 0; US3: marked hypoechoogenicity = 1, other echogenicity = 0; US4: microlobulated margin = 1, well-circumscribed or irregular margin = 0; US5: irregular margin = 1, well-circumscribed or microlobulated margin = 0; US6: microcalcification = 1, macrocalcification or no calcification = 0; US7: macrocalcification = 1, microcalcification or no calcification = 0; US8: taller-than-wide shape = 1, wider-than-tall shape = 0.

malignant initial cytologic results that had not undergone surgery as malignant. False-negative (5.8%) and false-positive (1.9%) cytologic results (16,27) may have had an effect on our results but were not considered. Fourth, we included only thyroid nodules that had undergone US-guided FNAB. At our institution, US-guided FNAB is usually performed on either a thyroid nodule with suspicious US features or the largest nodule if no suspicious US features are detected. In our study, 1618 patients underwent US-guided FNAB of only one nodule. Therefore, this selection bias may have affected the risk of cancer. In addition, we did not calculate the risk of cancer in patients with solitary nodules versus those with multiple nodules. Fifth, although the risk of malignancy

in our study was similar to the levels suggested in BI-RADS (12–14), when compared with other studies (12,13) the fitted probability of malignancy for each suspicious US feature had a relatively wide range. The fitted probability of malignancy was the lowest (0.036) when the thyroid nodule was a solid mass without any suspicious US features. In contrast, the fitted probability of malignancy was relatively higher in thyroid nodules with microcalcifications alone (0.109) and in those with microlobulated margins alone (0.127), and these values were higher than those in nodules with two suspicious US features—solid and hypoechoogenicity—combined (0.068–0.093). However, we considered TIRADS group 4a as nodules with only one suspicious US feature

because this scoring system focused on its simplicity and convenience. Sixth, we did not evaluate the cost-effectiveness or follow-up management of TIRADS 4a nodules, which have a relatively low risk of malignancy, when this system is applied. Further studies are needed to document this. Finally, the risk of malignancy in each category of this TIRADS referred to those in BI-RADS categories (12–14). However, the clinical aggressiveness and prevalence of nodules of these two cancers are definitely different.

In conclusion, risk stratification of thyroid malignancy according to the number of suspicious US features allows for a practical and convenient TIRADS.

**Acknowledgments:** The authors thank Chung Mo Nam, PhD, and Inkyung Jung, PhD, for their help with the statistics.

**Disclosures of Potential Conflicts of Interest:** **J.Y.K.** No potential conflicts of interest to disclose. **K.H.H.** No potential conflicts of interest to disclose. **J.H.Y.** No potential conflicts of interest to disclose. **H.J.M.** No potential conflicts of interest to disclose. **E.J.S.** No potential conflicts of interest to disclose. **S.H.P.** No potential conflicts of interest to disclose. **H.K.J.** No potential conflicts of interest to disclose. **J.S.C.** No potential conflicts of interest to disclose. **B.M.K.** No potential conflicts of interest to disclose. **E.K.K.** No potential conflicts of interest to disclose.

## References

- Fagin JA, Mitsiades N. Molecular pathology of thyroid cancer: diagnostic and clinical implications. *Best Pract Res Clin Endocrinol Metab* 2008;22(6):955–969.
- Papini E, Guglielmi R, Bianchini A, et al. Risk of malignancy in nonpalpable thyroid nodules: predictive value of ultrasound and color-Doppler features. *J Clin Endocrinol Metab* 2002;87(5):1941–1946.
- Koike E, Noguchi S, Yamashita H, et al. Ultrasonographic characteristics of thyroid nodules: prediction of malignancy. *Arch Surg* 2001;136(3):334–337.
- Kim EK, Park CS, Chung WY, et al. New sonographic criteria for recommending fine-needle aspiration biopsy of nonpalpable solid nodules of the thyroid. *AJR Am J Roentgenol* 2002;178(3):687–691.
- Moon WJ, Jung SL, Lee JH, et al. Benign and malignant thyroid nodules: US differentiation—multicenter retrospective study. *Radiology* 2008;247(3):762–770.
- Gharib H, Papini E, Valcavi R, et al. American Association of Clinical Endocrinologists and Associazione Medici Endocrinologi medical guidelines for clinical practice for the diagnosis and management of thyroid nodules. *Endocr Pract* 2006;12(1):63–102.
- American Thyroid Association (ATA) Guidelines Taskforce on Thyroid Nodules and Differentiated Thyroid Cancer, Cooper DS, Doherty GM, et al. Revised American Thyroid Association management guidelines for patients with thyroid nodules and differentiated thyroid cancer. *Thyroid* 2009;19(11):1167–1214.
- Frates MC, Benson CB, Charboneau JW, et al. Management of thyroid nodules detected at US: Society of Radiologists in Ultrasound consensus conference statement. *Radiology* 2005;237(3):794–800.
- Peccin S, de Castros JA, Furlanetto TW, Furtado AP, Brasil BA, Czepielewski MA. Ultrasonography: is it useful in the diagnosis of cancer in thyroid nodules? *J Endocrinol Invest* 2002;25(1):39–43.
- Chan BK, Desser TS, McDougall IR, Weigel RJ, Jeffrey RB Jr. Common and uncommon sonographic features of papillary thyroid carcinoma. *J Ultrasound Med* 2003;22(10):1083–1090.
- Cappelli C, Castellano M, Pirola I, et al. The predictive value of ultrasound findings in the management of thyroid nodules. *QJM* 2007;100(1):29–35.
- Park JY, Lee HJ, Jang HW, et al. A proposal for a thyroid imaging reporting and data system for ultrasound features of thyroid carcinoma. *Thyroid* 2009;19(11):1257–1264.
- Horvath E, Majlis S, Rossi R, et al. An ultrasonogram reporting system for thyroid nodules stratifying cancer risk for clinical management. *J Clin Endocrinol Metab* 2009;94(5):1748–1751.
- American College of Radiology. Breast imaging reporting and data system, breast imaging atlas. 4th ed. Reston, Va: American College of Radiology, 2003.
- Anderson L, Middleton WD, Teehey SA, et al. Hashimoto thyroiditis. I. Sonographic analysis of the nodular form of Hashimoto thyroiditis. *AJR Am J Roentgenol* 2010;195(1):208–215.
- Kwak JY, Kim EK, Kim HJ, Kim MJ, Son EJ, Moon HJ. How to combine ultrasound and cytological information in decision making about thyroid nodules. *Eur Radiol* 2009;19(8):1923–1931.
- Cibas ES, Ali SZ. The Bethesda system for reporting thyroid cytopathology. *Thyroid* 2009;19(11):1159–1165.
- Yoon JH, Kwak JY, Kim EK, et al. How to approach thyroid nodules with indeterminate cytology. *Ann Surg Oncol* 2010;17(8):2147–2155.
- Kwak JY, Kim EK, Kim MJ, et al. The role of ultrasound in thyroid nodules with a cytology reading of “suspicious for papillary thyroid carcinoma.” *Thyroid* 2008;18(5):517–522.
- Davies L, Welch HG. Increasing incidence of thyroid cancer in the United States, 1973–2002. *JAMA* 2006;295(18):2164–2167.
- Kent WD, Hall SF, Isotalo PA, Houlden RL, George RL, Groome PA. Increased incidence of differentiated thyroid carcinoma and detection of subclinical disease. *CMAJ* 2007;177(11):1357–1361.
- Abdullah N, Mesurole B, El-Khoury M, Kao E. Breast imaging reporting and data system lexicon for US: interobserver agreement for assessment of breast masses. *Radiology* 2009;252(3):665–672.
- Kim EK, Ko KH, Oh KK, et al. Clinical application of the BI-RADS final assessment to breast sonography in conjunction with mammography. *AJR Am J Roentgenol* 2008;190(5):1209–1215.
- Gharib H, Papini E, Paschke R, et al. American Association of Clinical Endocrinologists, Associazione Medici Endocrinologi, and European Thyroid Association Medical guidelines for clinical practice for the diagnosis and management of thyroid nodules: executive summary of recommendations. *Endocr Pract* 2010;16(3):468–475.
- Frates MC, Benson CB, Doubilet PM, et al. Prevalence and distribution of carcinoma in patients with solitary and multiple thyroid nodules on sonography. *J Clin Endocrinol Metab* 2006;91(9):3411–3417.
- Choi SH, Kim EK, Kwak JY, Kim MJ, Son EJ. Interobserver and intraobserver variations in ultrasound assessment of thyroid nodules. *Thyroid* 2010;20(2):167–172.
- Kwak JY, Koo H, Youk JH, et al. Value of US correlation of a thyroid nodule with initially benign cytologic results. *Radiology* 2010;254(1):292–300.